

US-guided percutaneous microwave ablation for the treatment of benign thyroid nodules

Wenjun Wu^{1),2)*}, Xiaohua Gong^{2)*}, Qi Zhou²⁾, Xiong Chen²⁾, Xiaojun Chen²⁾ and Bimin Shi¹⁾

¹⁾ Department of Endocrinology and Metabolism, The First Affiliated Hospital of Soochow University; Suzhou 215006 China

²⁾ Department of Endocrinology and Metabolism, The First Affiliated Hospital of Wenzhou Medical University, Wenzhou 325000, China

Abstract. The aim of this study was to define the effectiveness and safety of ultrasound(US)-guided percutaneous microwave ablation(MWA) for benign thyroid nodules with one session treatment. A total 121 benign thyroid nodules in 100 euthyroid patients underwent MWA in one medical center between August 2014 and December 2015. MWA was performed with an internally cooled antenna under local anesthesia. The volume of the nodule, cosmetic score and symptom score were compared before and after the procedure. The volume reduction rate(VRR) was also evaluated. The side effect and complications were observed. As a result, microwave ablation was associated with a significant decrease in nodule volume {1.05±1.05mL (0.08~4.33mL) vs 8.56±4.21mL(4.05~22.66mL), $p<0.001$ } at 12-month follow-up. The largest diameter was also decreased {1.36±0.53cm(0.60~3.73cm) vs 2.94±0.55cm(2.00~4.40cm) , $p<0.001$ }. The symptom score and cosmetic score were decreased significantly after the procedure(1.71±0.68 vs 3.31±1.13, $p<0.001$; 1.16±0.37 vs 2.37±0.94, $p<0.001$). The VRR was 57.66±22.95%, .70.23±20.07%, 85.97±14.04% at 3-, 6- and 12-month follow-up after ablation , respectively. Two patients(2.0%) experienced hoarseness and recovered within 2 months. Two patients(2.0%) developed slight burn on cervical skin. One case(1%) developed Horner Syndrome, recovered within 2 months. Ultrasound-guided percutaneous microwave ablation developed significant volume reduction on benign thyroid nodules, with achieving improvement in symptom score and cosmetic grading. The treatment was well tolerated.

Key words: Microwave ablation, Thyroid nodules, Ultrasound-guided, Thermal ablation

THYROID NODULES(TN) is one of the most common thyroid diseases. According to the recent survey, the prevalence of TN was 46.6 % and it increased with increasing age among the population aged>40 years old in China [1]. Most thyroid nodules are benign, but some nodules require treatment for subjective symptoms, cosmetic reasons and anxiety about a malignant change [2]. Surgery is the long-established therapeutic option for benign thyroid nodules, which steadily grow and become symptomatic. The cost of thyroid surgery, the risk of temporary or permanent complications, and the effect on quality of life, however, remain relevant concerns. Therefore, various minimally invasive treatments, directed towards office-based management of symptomatic nodules, with-

out requiring general anesthesia, and with negligible damage to the skin and cervical tissues, have been proposed during the past two decades. Thermal ablation using laser, radiofrequency and microwave techniques have demonstrated good results in recent years [3-6]. Radiofrequency ablation(RFA) exhibited a significant improvement of quality of life when compared to open thyroidectomy [7]. Previous studies on microwave ablation(MWA) identified the efficacy and safety for initial experience, however there are limitations on small sample or short time follow-up [6,8]. Our study was to define the effectiveness and safety of microwave ablation for benign thyroid nodules in 1 year, as well as the improvements of symptoms and cosmetic problems.

Submitted Apr. 14, 2017; Accepted Jul. 24, 2017 as EJ17-0152
Released online in J-STAGE as advance publication Aug. 29, 2017
Correspondence to: Bimin Shi, Department of Endocrinology and Metabolism, The First Affiliated Hospital of Soochow University, No.899 Pinghai Road, Suzhou 215006, China.
E-mail: shibimin@163.com

Correspondence to: Xiaojun Chen, Department of Endocrinology and Metabolism, The First Affiliated Hospital of Wenzhou Medical University, No. 2 Fuxue Lane, Wenzhou 325000, China.
E-mail: Chenxj@medmail.com.cn

* The two authors contributed equally to this work.

Material and Methods

Patients

All patients of this study were signed in written informed consent. The protocol was approved by Ethics Committee of Wenzhou Medical University. This study is a retrospective study design. There were 100 patients with a total of 121 thyroid nodules recruited from August 2014 to December 2015 in thyroid center in one institution, who received microwave ablation for the treatment. The inclusion criteria for all the patients were as follows: (1) with predominantly solid (solid component >80%) or cystic and solid mixed nodule (solid component 50~80%) on ultrasound; (2) with complaints of pressure symptoms, throat constraint, and/or swallowing difficulty or esthetic problems. (3) benign cytology that means colloid and sheets of follicular cells without atypia, class 2 [9]. (4) ineligibility or refusal to undergo surgery. (5) with normal thyroid function. Twenty-eight cases were male, 72 cases were female, aged 19-66 years old, average 42.00 ± 11.57 years old, 49 nodules on the left lobe, 52 on the other side and 20 in the isthmus, fine-needle aspiration cytology (FNAC) were conducted before operation to make sure of benign thyroid lesions. Those who had received the medication of anti-thyroid drugs or levo-thyroxine were ineligible.

Equipment and Preoperative preparation

Nanjing YIGAO company ECO-100 multi-functional microwave therapeutic instrument (YIGAO Microwave System Engineering Co.Ltd, Nanjing, Jiangsu Province, China) was applied with disposable microwave antenna (16G), output power setting was 35W, the output frequency was 2,450 MHz, the internally cooled microwave antenna with normal saline for cold fluid circulation was used. The diameter, composition, vascularity of nodules were examined by Phillip iU22 color Doppler ultrasonic diagnostic apparatus, probe frequency 5~12MHz, preoperative, intraoperative and postoperative of thyroid nodules were examined by two-dimensional respectively, color Doppler flow and contrast-enhanced ultrasonography (CEUS) examination was also performed.

Laboratory data including blood biochemistry analysis, complete blood count, blood coagulation test (prothrombin time and activated partial thromboplastin time), thyroid function (Thyroid Stimulating Hormone TSH, triiodothyronine TT3, thyroxine TT4,

free triiodothyronine FT3, free thyroxine FT4) and thyroid peroxidase antibody (TPOAb) and thyroglobulin antibody (TGAb) were assessed. Electrocardiogram (ECG) was examined.

Procedure

With the supine cervical extension, a venous catheter was inserted in a forearm vein. Local anesthesia with 2% lidocaine was given subcutaneously on the puncture site. A multiparametric monitor was connected to the patient showing continuous blood pressure, oxyhemoglobin saturation, and electrocardiogram during the procedure.

According to the different position of thyroid nodules, the solution mixed with saline and 2% lidocaine was injected between the thyroid and carotid space, thyroid and trachea gap, thyroid and esophageal groove and trachea-esophageal groove. Under the guidance of ultrasound, hydrodissection technique was used in order to protect the important structures from thermal damage (Fig. 1A). After that, the disposable microwave antenna was placed percutaneously into the nodule along its short axis under ultrasound guidance, pedal started microwave therapeutic instrument, during the microwave ablation, a power output of 35W was usually used and the variations in the echo from the nodule were monitored by real-time ultrasound. The procedure was conducted in 'moving-shot technique' [3]. The extent of ablation area was presumed by the echogenic change around the antenna. If the transient hyperechoic zone did not completely cover the entire nodule at one site, the tip of the antenna was moved backward. The microwave antenna was repositioned and other parts of the nodule were treated when necessary. The ablation was not stopped until the transient hyperechoic zone covered the whole nodule (Fig. 1B). If there was some partially cystic nodules, drain the liquid and then the solid component and cyst wall were ablated. Before and after ablation, the application of high frequency ultrasound on nodule location, size, texture and with surrounding tissue adjacent relations was carried out for detailed observation and recording. Before and immediately after ablation, the nodules were checked by contrast enhanced ultrasound observation of filling defect area. Nonenhancement was shown as a consequence of coagulative necrosis induced by MWA. Time consumed for each nodule was recorded, and mechanical compression for 20-30min was needed on the neck to prevent bleeding or hematoma formation [6].

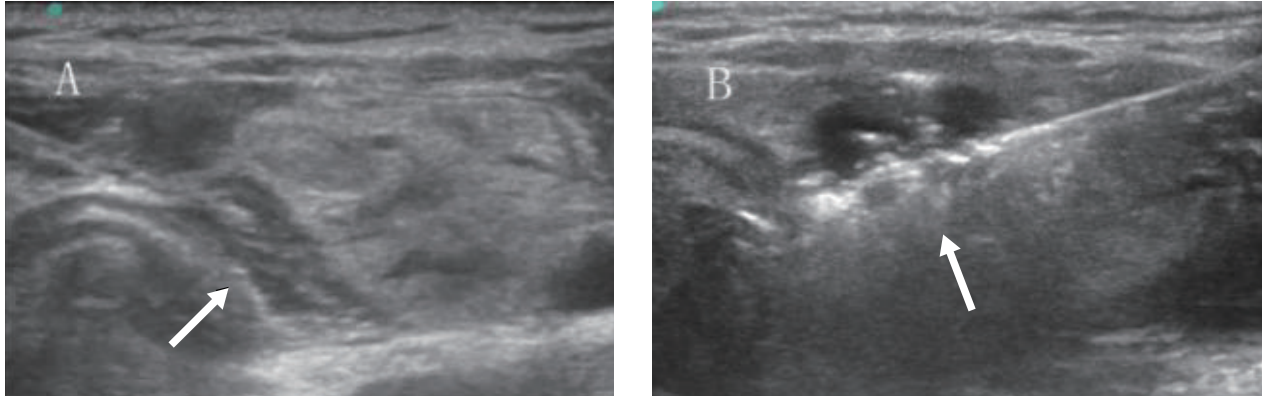


Fig. 1 Procedure of the microwave ablation

A, Hydrodissection; **B**, Microwave antenna working state and ultrasonogram change in the thyroid nodule.

A 33-year-old woman had a predominant solid benign nodule in the right lobe of her thyroid gland. Here is the key procedure of the treatment. **(A)** Hydrodissection (arrow) was used by the injection of mixture of 2% lidocaine and saline, protecting the vital structures of the neck (carotid artery, trachea, esophagus, nerve) from the thermal injury. **(B)** During the procedure, an internally cooled microwave antenna (16G) was positioned in the thyroid nodule. Sonogram showed typical transient hyperechoic zone (arrow) surrounding antenna.

Observational Values

Before ablation and after that of 1, 3, 6, 9, 12 months respectively, the patients need back to hospital for follow-up review. Preoperative, postoperative thyroid function tests, thyroid globulin antibody, thyroid peroxidase antibody, thyroid ultrasonography were performed. Ultrasonography was examined by fixed technologists in the same ultrasound machines, three orthogonal diameters of thyroid nodules were measured. The volume of the nodules was calculated by the following equation: $V = \pi abc/6$ (V : volume, a : the largest diameter, b and c : the other two perpendicular diameters).

Clinical symptoms were evaluated using the symptom grading scores (visual analog scale, 0-10cm), and the cosmetic grading scores (grade 1: no palpable mass, grade 2: invisible but palpable mass, grade 3: visible mass only by experienced clinician's eyes, and grade 4: easily visible mass) [10].

Statistical analysis

Data analysis was performed with statistical software (SPSS for Windows version 19.0 SPSS IBM Corp, New York, USA). Values for quantitative variables were expressed as mean \pm standard deviation (SD). Variables at enrollment and the follow-up visit were compared by Wilcoxon's signed rank test. Enumeration

data using chi square test. Differences were considered significant when the p value was <0.05 .

Results

Nonenhancement was shown on contrast-enhanced ultrasound after treatment as a consequence of coagulative necrosis induced by MWA. The volume of the index nodule decreased from $8.56 \pm 4.21 \text{ mL}$ ($4.05 \sim 22.66 \text{ mL}$) before ablation to $1.05 \pm 1.05 \text{ mL}$ ($0.08 \sim 4.33 \text{ mL}$) at the follow-up one year after procedure ($p < 0.001$), see Fig. 2. The largest diameter was also decreased from $2.94 \pm 0.55 \text{ cm}$ ($2.00 \sim 4.40 \text{ cm}$) to $1.36 \pm 0.53 \text{ cm}$ ($0.60 \sim 3.70 \text{ cm}$) at 12-month follow-up ($p < 0.001$). The ablated time was 1~17min, average $6.43 \pm 4.02 \text{ min}$. Initial mean FT3, FT4 and TSH were $4.18 \pm 1.20 \text{ pmol/L}$, $10.02 \pm 3.01 \text{ pmol/L}$ and $1.91 \pm 2.33 \text{ mIU/L}$ respectively. There was no change of mean FT3, FT4 and TSH (FT3 $4.26 \pm 0.99 \text{ pmol/L}$, FT4 $11.19 \pm 2.49 \text{ pmol/L}$, TSH $1.72 \pm 0.82 \text{ mIU/L}$, $p = 0.944, 0.968, 0.747$). The symptom grading score was reduced from 3.31 ± 1.13 to 1.71 ± 0.68 ($p < 0.001$), and cosmetic grading score was reduced from 2.37 ± 0.94 to 1.16 ± 0.37 ($p < 0.001$). See Table 1.

The mean volume decreased from $8.56 \pm 4.21 \text{ mL}$ to $5.46 \pm 3.11 \text{ mL}$, $3.44 \pm 2.34 \text{ mL}$, $2.33 \pm 1.77 \text{ mL}$, $1.05 \pm 1.05 \text{ mL}$ at 1-, 3-, 6-, 12-month follow-up. Meanwhile,

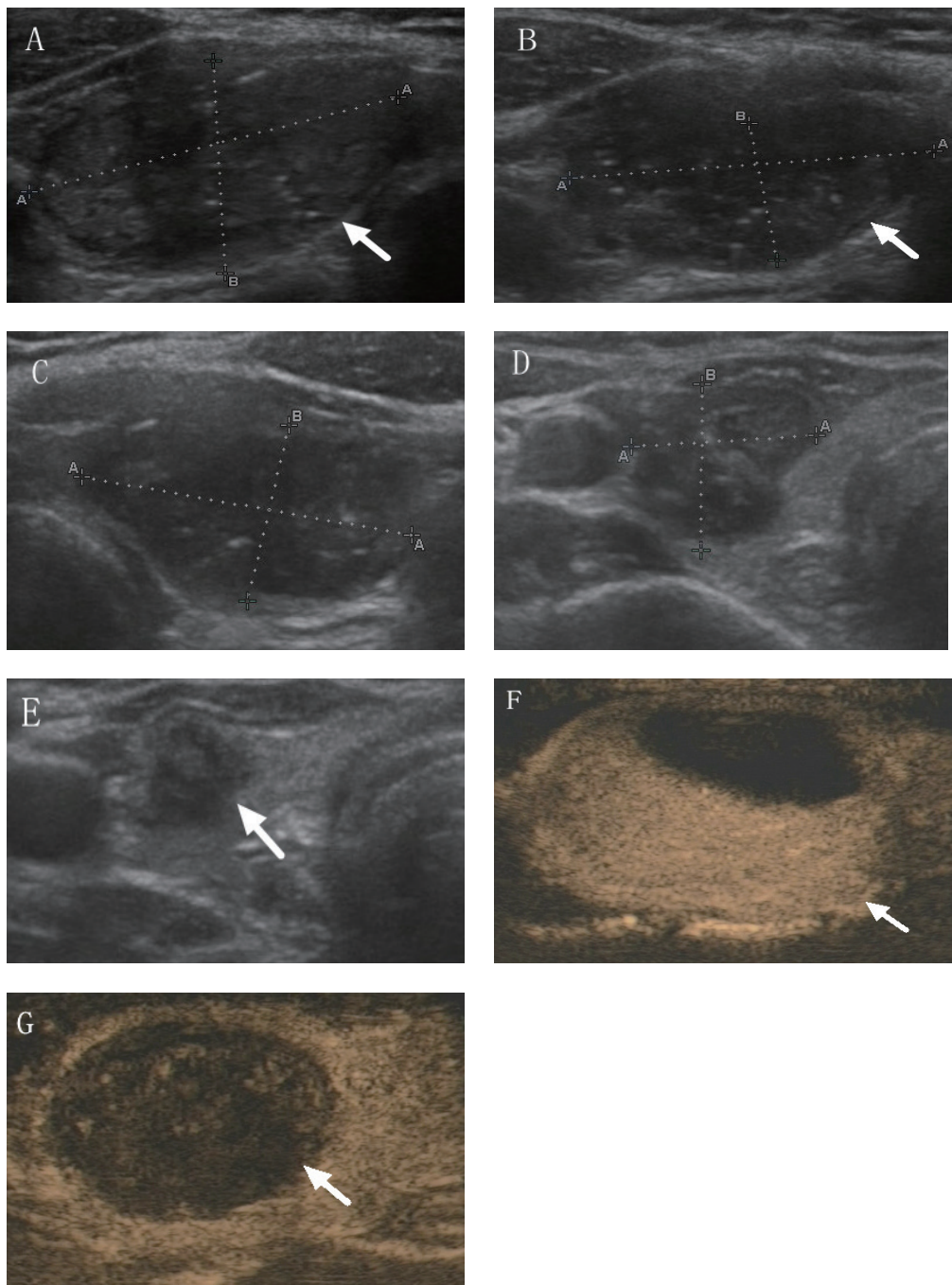


Fig. 2 The changes on the volume of the nodules before MWA and at each follow-up period

A 36-year-old woman had a mainly solid nodule in the left lobe of her thyroid gland. The changes on the volume of the nodules before MWA and at each follow-up period were presented in the following pictures. **(A)** Ultrasound examination reveal the nodule size to be 3.29cm×1.66cm×2.62cm, nodule volume to be 7.48ml before ablation. **(B)** At follow-up ultra sonography examination 1-month after treatment, the volume of nodule was reduced to 5.00ml. **(C)** Thyroid nodule volume was reduced to 3.97ml at 3-month follow-up. **(D)** Six month after the procedure, the volume of thyroid nodule continued to decreased to 1.45ml. **(E)** At 1-year follow-up after the treatment, the volume of nodule reduced to 0.21ml, 2.8% of original. **(F)** Before MWA, enhanced-contrast ultrasound was performed on the patient. Pre-ablation the nodule was highly enhanced on enhanced-contrast ultrasound(arrow). **(G)** Non-enhancement (arrow) was showed on the nodule after the procedure on contrast-enhanced ultrasonography.

Table 1 Baseline and the change of values after 1 year follow-up

	Volume (ml)	Largest diameter (cm)	Symptom score	Cosmetic score	FT3 (pmol/L)	FT4 (pmol/L)	TSH (mIU/L)	TGAb (IU/ml)	TPOAb (IU/ml)
Pre-ablation	8.56±4.21	2.94±0.55	3.31±1.13	2.37±0.94	4.18±1.20	10.02±3.01	1.91±2.33	<0.90 (0.00-73.10)	0.80 (0.00-448.90)
After-ablation	1.05±1.05**	1.36±0.53	1.71±0.68**	1.16±0.37**	4.26±0.99	11.19±2.49	1.72±0.82	<0.90 (0.00-182.50)	0.80 (0.50-443.60)
Change	1.20±1.53	1.58±0.61	1.59±0.77	1.20±0.79	-0.10±0.87	-1.16±4.68	0.20±2.26	-	-
<i>p</i> value	<0.001	<0.001	<0.001	<0.001	0.944	0.968	0.747	0.180	0.248

TGAb and TPOAb are presented as median and range.

the mean volume reduction rate(VRR) at 3, 6 and 12 months after ablation was 57.66±22.95%, 70.23±20.07%, 85.97±14.04%, respectively (shown in Fig. 3). At 12-month follow-up, there were 89.4% nodules which volume reduction rate achieved more than 50% [11].

Safety

All the patients received microwave ablation well tolerated to the procedure. Ten patients (10.0%) complained of various degrees of pain at ablated site, or pain radiating to the ear, shoulder or teeth, but can stand. The pain totally relieved when the ablation finished. No one needed analgesics. There were no hematoma formation developed. Ten patient(10%) encountered voice change after procedure, and 2 in 10 recoverd within 2 months under the treatment of neurotrophic drugs. The others recovered within 24 hours spontaneously. Slight skin burn happened in two cases(2.0%). One patients (1.0%) suffered from Horner syndrome, mainly for ptosis and pupil shrinks, within 2 months recovered to normal. There were no serious complications such as esophageal perforation and tracheal injury.

Discussion

Thyroid nodules(TNs) have annual increasing trends worldwide, and the prevalence in China is relatively high [12]. For benign TNs, surgery involves some drawback and complications such as nerve injury and scar formation [13]. Levothyroxine(LT4) suppressive therapy is not recommended in euthyroid patients with benign thyroid nodules [14]. Non-surgical treatment options were used to treat benign thyroid nodules. Those modalities have achieved great efficacy and mild complications [3, 5, 6, 15, 16].

Ethanol ablation is more suitable to treat cyst or pre-dominant cyst benign thyroid nodules [11, 17, 18]. In

this study, we conducted microwave ablation for the 121 predominant solid or mixed benign thyroid nodules, one-year follow-up demonstrated the significant reduction in nodule volume. The symptom grading score and cosmetic grading score were also significantly improved. MWA heats tissue to cytotoxic level through which cell death is caused. Afterwards the created coagulative necrosis is degraded by the patients' own immune system [19]. It is comparable to the radiofrequency ablation in light of volume reduction rate [3, 20, 21]. But we needed less ablated time when microwave ablation was chosen. Nodules larger than 4.0ml were enrolled in our study, but the mean ablated time was 6.43 minutes. The time was significant shorter than that of RFA studies [3, 4]. It probably due to the advantages of the microwave technique. When compared with other thermoablative technologies, the main advantages of the microwave ablation includes consistently higher intratumoral temperatures, larger tumor ablation volumes, faster ablation times, and an improved convection profile [22]. Our study showed that MWA not only achieved good effect on VRRs, but also made the procedure more time-effective.

Some complications encountered in this study. Recurrent laryngeal nerve palsy and cervical sympathetic ganglia injury happened in 2 patients and 1 patient, respectively. Clinical manifestations includes hoarseness, ptosis, and corestenoma. The patients recovered within 2 months. The incidence of recurrent laryngeal nerve palsy was a little higher than that of some previous reports [5, 20, 23-25]. However, iatrogenic nerve injury cannot be avoid completely even in surgery. Minor complications was similar to what was reported with RFA and laser ablation [3, 5, 20]. Pain was the most common complaints of the patients during the procedure. It occasionally radiates to ear, shoulder, jaw and upper chest. But it was usually self-limiting and resolved when the power of the microwave device had been switched off.

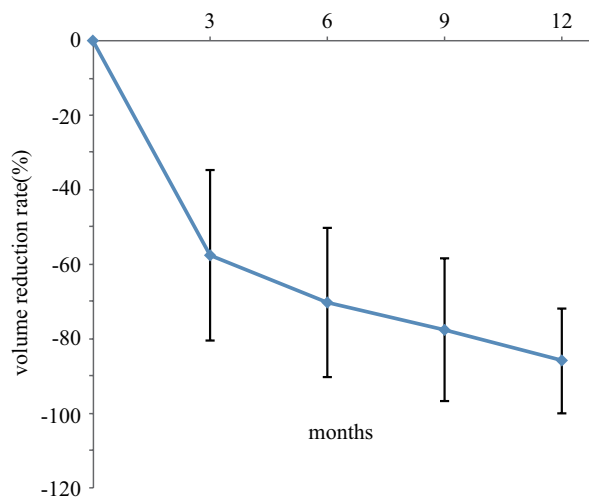


Fig. 3 Continuous decreases in VRR after microwave ablation
Comparison of the mean volume reduction rate(VRR) of the nodules at baseline(time of microwave ablation) and at follow-up after treatment. The VRR at 3-, 6-, 9- and 12-month was $57.66\pm 22.95\%$, $70.23\pm 20.07\%$, $77.56\pm 19.15\%$ and $85.97\pm 14.04\%$.

There were some limitation in this study. Eight patients complained of transient voice change but they recovered within 24 hours. We supposed it may be caused by the protective hydrodissection technique, which made of mixed solution with local anesthetics and saline. It was due to compression of the liquid and the anesthetic effect. The hydrodissection technique by injection of mixture of lidocaine and saline seemed not be perfect. The solution was usually absorbed within several minutes. So sometime we needed to repeat the injection. On the other hand, we conducted through lateral cervical approach for more cases, this may increase the possibilities of nerve injury when nodule located inner-lower in

the thyroid gland. In addition, MWA has a much larger area of active heating compared with RFA.

Secondly, cyst and solid mixed nodules were also enrolled in this study, we conducted MWA after liquid was aspirated completely for such nodules, that will possibly improve the value of VRR [26]. Moreover, it is not a prospective study, and we retrospectively compared the nodule volume before and after procedure. No control group was compared. The sample size of the study is not large, and the follow-up is not long-time observation. Therefore, although the application of microwave ablation of benign thyroid nodules achieved good effect, long-term and large-scale studies need to be developed.

In conclusion, our study shows that US-guided percutaneous microwave ablation seems to be an effective and minimally invasive technique for the treatment of benign thyroid nodules, decreasing nodule volumes, improving the related symptoms and cosmetic appearances. Microwave ablation is safe as few procedure-related major complications occur. MWA can be considered as an alternative option to treat benign thyroid nodules.

Acknowledgements

We are sincerely grateful to all of the patients studied in this research. This study was supported by Scientific Research Programme of Zhejiang Medical Association (No.2015ZYC-A25) and Scientific Incubation Programme of Wenzhou Medical University First Affiliated Hospital(No. FHY2015022)

Disclosure

None of the authors have any potential conflicts of interest associated with this research.

References

- Guo H, Sun M, He W, Chen H, Li W, *et al.* (2014) The prevalence of thyroid nodules and its relationship with metabolic parameters in a Chinese community-based population aged over 40 years. *Endocrine*. 45: 230-235.
- Weiss RE, Lado-Abeal J (2002) Thyroid nodules: diagnosis and therapy. *Curr Opin Oncol* 14: 46-52.
- Jeong WK, Baek JH, Rhim H, Kim YS, Kwak MS, *et al.* (2008) Radiofrequency ablation of benign thyroid nodules: safety and imaging follow-up in 236 patients. *Eur Radiol* 18: 1244-1250.
- Li XL, Xu HX, Lu F, Yue WW, Sun LP, *et al.* (2016) Treatment efficacy and safety of ultrasound-guided percutaneous bipolar radiofrequency ablation for benign thyroid nodules. *Br J Radiol* 89(1059): 20150858.
- Valcavi R, Riganti F, Bertani A, Formisano D, Pacella CM (2010) Percutaneous laser ablation of cold benign thyroid nodules: a 3-year follow-up study in 122 patients. *Thyroid* 20: 1253-1261.
- Yue W, Wang S, Wang B, Xu Q, Yu S, *et al.* (2013) Ultrasound guided percutaneous microwave ablation of

- benign thyroid nodules: safety and imaging follow-up in 222 patients. *Eur J Radiol* 82: e11-e16.
7. Yue WW, Li XL, Xu HX, Lu F, Sun LP, *et al.* (2016) Quality of Life and Cost-Effectiveness of Radiofrequency Ablation versus Open Surgery for Benign Thyroid Nodules: a retrospective cohort study. *Sci Rep* 6: 37838.
 8. Feng B, Liang P, Cheng Z, Yu X, Yu J, *et al.* (2012) Ultrasound-guided percutaneous microwave ablation of benign thyroid nodules: experimental and clinical studies. *Eur J Endocrinol* 166: 1031-1037.
 9. Cibas ES, Ali SZ (2009) The Bethesda System for Reporting Thyroid Cytopathology. *Thyroid* 19: 1159-1165.
 10. Baek JH, Kim YS, Lee D, Huh JY, Lee JH (2010) Benign predominantly solid thyroid nodules: prospective study of efficacy of sonographically guided radiofrequency ablation versus control condition. *AJR Am J Roentgenol* 194: 1137-1142.
 11. Sung JY, Baek JH, Kim KS, Lee D, Yoo H, *et al.* (2013) Single-session treatment of benign cystic thyroid nodules with ethanol versus radiofrequency ablation: a prospective randomized study. *Radiology* 269: 293-300.
 12. Chen Z, Xu W, Huang Y, Jin X, Deng J, *et al.* (2013) Associations of noniodized salt and thyroid nodule among the Chinese population: a large cross-sectional study. *Am J Clin Nutr* 98: 684-692.
 13. Che Y, Jin S, Shi C, Wang L, Zhang X, *et al.* (2015) Treatment of Benign Thyroid Nodules: Comparison of Surgery with Radiofrequency Ablation. *AJNR Am J Neuroradiol* 36: 1321-1325.
 14. Gharib H, Papini E, Garber JR, Duick DS, Harrell RM, *et al.* (2016) AMERICAN ASSOCIATION OF CLINICAL ENDOCRINOLOGISTS, AMERICAN COLLEGE OF ENDOCRINOLOGY, AND ASSOCIAZIONE MEDICI ENDOCRINOLOGI MEDICAL GUIDELINES FOR CLINICAL PRACTICE FOR THE DIAGNOSIS AND MANAGEMENT OF THYROID NODULES--2016 UPDATE. *Endocr Pract* 22: 622-639.
 15. Sung JY, Kim YS, Choi H, Lee JH, Baek JH (2011) Optimum first-line treatment technique for benign cystic thyroid nodules: ethanol ablation or radiofrequency ablation. *AJR Am J Roentgenol* 196: W210-W214.
 16. Wong KP, Lang BH (2013) Use of radiofrequency ablation in benign thyroid nodules: a literature review and updates. *Int J Endocrinol* 2013: 428363.
 17. Gharib H, Hegedus L, Pacella CM, Baek JH, Papini E (2013) Clinical review: Nonsurgical, image-guided, minimally invasive therapy for thyroid nodules. *J Clin Endocrinol Metab* 98: 3949-3957.
 18. Kim JH, Lee HK, Lee JH, Ahn IM, Choi CG (2003) Efficacy of sonographically guided percutaneous ethanol injection for treatment of thyroid cysts versus solid thyroid nodules. *AJR Am J Roentgenol* 180: 1723-1726.
 19. Korkusuz Y, Mader OM, Kromen W, Happel C, Ahmad S, *et al.* (2016) Cooled microwave ablation of thyroid nodules: Initial experience. *Eur J Radiol* 85: 2127-2132.
 20. Kim YS, Rhim H, Tae K, Park DW, Kim ST (2006) Radiofrequency ablation of benign cold thyroid nodules: initial clinical experience. *Thyroid* 16: 361-367.
 21. Spiezia S, Garberoglio R, Milone F, Ramundo V, Caiazzo C, *et al.* (2009) Thyroid nodules and related symptoms are stably controlled two years after radiofrequency thermal ablation. *Thyroid* 19: 219-225.
 22. Simon CJ, Dupuy DE, Mayo-Smith WW (2005) Microwave ablation: principles and applications. *Radiographics* 25 Suppl 1: S69-83.
 23. Jang SW, Baek JH, Kim JK, Sung JY, Choi H, *et al.* (2012) How to manage the patients with unsatisfactory results after ethanol ablation for thyroid nodules: role of radiofrequency ablation. *Eur J Radio* 181: 905-910.
 24. Baek JH, Lee JH, Sung JY, Bae JI, Kim KT, *et al.* (2012) Complications encountered in the treatment of benign thyroid nodules with US-guided radiofrequency ablation: a multicenter study. *Radiology* 262: 335-342.
 25. Kim C, Lee JH, Choi YJ, Kim WB, Sung TY, *et al.* (2017) Complications encountered in ultrasonography-guided radiofrequency ablation of benign thyroid nodules and recurrent thyroid cancers. *Eur Radiol* 27:3128-3137.
 26. Mader OM, Tanha NF, Mader A, Happel C, Korkusuz Y, *et al.* (2017) Comparative study evaluating the efficiency of cooled and uncooled single-treatment MWA in thyroid nodules after a 3-month follow up. *Eur J Radiol Open* 4: 4-8.