

## CLINICAL STUDY

# Ultrasound-guided percutaneous microwave ablation of benign thyroid nodules: experimental and clinical studies

Bing Feng, Ping Liang, Zhigang Cheng, Xiaoling Yu, Jie Yu, Zhiyu Han and Fangyi Liu

Department of Interventional Ultrasound, Chinese People's Liberation Army General Hospital, 28 Fuxing Road, Beijing 100853, People's Republic of China

(Correspondence should be addressed to P Liang; Email: liangping301@hotmail.com)

## Abstract

**Purpose:** To obtain the treatment parameters of internally cooled microwave antenna and to evaluate the feasibility of ultrasound-guided percutaneous microwave ablation (MWA) for benign thyroid nodules.

**Materials and methods:** MWAs were performed by microwave antenna (16G) in *ex vivo* porcine liver. The lesion diameters achieved in different groups (20, 25, and 30 W for 3, 5, 7, 10, and 12 min) were compared. The clinical study was approved by the ethics committee. Written informed consent was obtained from all patients. MWA was performed in 11 patients (male to female ratio = 1:10; mean age,  $50 \pm 7$  years) with 11 benign thyroid nodules. Ultrasound scan, laboratory data, and clinical symptoms were evaluated before and 1 day and 1, 3, 6, 9, and 12 months after the procedure.

**Results:** In *ex vivo* study, the ablation lesion at 30 W 12 min tended to have appropriate scope and spherical shape. In clinical study, the follow-up periods ranged from 1 to 9 months. At the last follow-up, the largest diameter decreased from  $2.9 \pm 1.0$  (range, 1.6–4.1) to  $1.9 \pm 0.7$  (range, 0.4–3.0) cm ( $P < 0.01$ ), and the volume decreased from  $5.30 \pm 4.88$  (range, 0.89–14.81) to  $2.40 \pm 2.06$  (range, 0.02–6.35) ml ( $P < 0.01$ ). The volume reduction ratio was  $45.99 \pm 29.90$  (range, 10.56–98.15) %. The cosmetic grading score was reduced from  $3.20 \pm 0.79$  to  $2.30 \pm 0.95$  ( $P < 0.05$ ). One patient experienced temporary nerve palsy and was recovered within 2 months after treatment.

**Conclusion:** The internally cooled microwave antenna can yield ideal ablation lesions, and ultrasound-guided percutaneous MWA is a feasible technique for benign thyroid nodules.

European Journal of Endocrinology 166 1031–1037

## Introduction

Thyroid nodules are found in 3–7% of the general population by means of palpation, and in 20–76% by means of ultrasound scan, with a prevalence similar to that reported from autopsy data (1). Most thyroid nodules are benign but some require treatment for cosmetic reasons, subjective symptoms, or anxiety about a malignant change (2). In cases of thyroid cytologically benign lesions, it is difficult to decide the best management for patients. Both surgical and conservative approaches have drawbacks. Surgery has problems including long hospitalization, general anesthesia, scar formation, iatrogenic hypothyroidism, and difficulty in reoperation. The conservative approach is not helpful for the uncomfortable feeling of a lump in the throat or cosmetic concerns. Therefore, nonsurgical, minimally invasive modalities, such as ethanol injection, laser ablation, and radiofrequency ablation (RFA), have been attempted, yielding good results (2, 3, 4, 5).


Microwave ablation (MWA) is a minimally invasive technique that has been used to treat benign and malignant tumors of liver, kidney, adrenal gland, spleen,

and lung by inducing tissue necrosis through heat (6, 7, 8, 9, 10); however, its use in thyroid nodules has not been reported. Compared with RFA, MWA may offer a larger ablation zone, less treatment time, and more complete tumor kill. MWA is also less affected by the perfusion-mediated heat sink effect, which may be helpful for treating tumors with a rich blood supply (11). The aim of our study is to obtain the treatment parameters of internally cooled microwave antenna, such as ablation shape, scope, and temperature rise curve and to evaluate the feasibility of ultrasound-guided percutaneous MWA for benign thyroid nodules.

## Materials and methods

### MWA equipment

A MWA instrument (KY-2000; Kangyou Medical, Nanjing, China) was used to administer microwave energy. The generator is capable of producing 1–100 W of power at 2450 MHz. The internally cooled needle antenna (16G) in this study is designed specially to treat superficial neck organ diseases. It has a diameter of



**Figure 1** Photographs of microwave antennae. Top: the antenna in this study, 16G, a 10 cm shaft, 3 mm between the narrow radiating segment and the tip of antenna (arrow). It is designed specially to treat superficial neck organ diseases. Bottom: 15G, an 18 cm shaft, 11 mm between the narrow radiating segment and the tip of antenna (arrow). It is used for abdominal tumors. Full colour version of this figure available via <http://dx.doi.org/10.1530/EJE-11-0966>.

1.6 mm and a 10 cm shaft coated with polytetrafluoroethylene to prevent tissue adhesion. A narrow radiating segment of 3 mm is embedded on the shaft, 3 mm away from the tip for 2450 MHz applicator (Fig. 1).

Iron–constantan thermocouple was used to measure the temperature in the *ex vivo* study. A thin insulation epoxy resin was used to insulate the metallic shaft of the thermocouple needle to avoid any interference from the metal in the electric field. A data acquisition (34970A, Hewlett Packard, CA, USA) with 16-bit analog output function was used.

### Experimental study

MWAs were performed in *ex vivo* porcine liver at room temperature (15–20 °C) for a range of treatment durations and power settings. Five time increments (3, 5, 7, 10, and 12 min) and three power increments (20, 25, and 30 W) were used, constituting 15 time–power combinations. For each combination of parameters, trials were performed four times, for a total of 60 ablations. The microwave antenna was submerged 6 cm into the liver to ensure that the entire ablation zone would be within the liver parenchyma. For each ablation, iron–constantan thermocouple was used to be inserted in the liver 5, 10, and 15 mm from the electrode-radiating segment to measure the temperature.

### Clinical study

**Patients** The study was prospective. The study was approved by our hospital ethics committee, and written informed consent was obtained from each patient. From November 2010 to August 2011, 11 patients (male to female ratio=1:10; mean age, 50±7 years; age range, 39–59 years) with 11 benign thyroid nodules (nine patients with nodular goiter and two with Hashimoto's thyroiditis) underwent ultrasound-guided percutaneous MWA with internally cooled antenna.

The inclusion criteria of this study were as follows: i) ultrasound criteria for benign nodule; ii) the presence

of subjective symptoms (neck discomfort or pain, foreign body sensation, and compressive symptom); iii) cosmetic problems, iv) ineligibility or refusal to undergo surgery; and v) anxiety about malignancy change.

The exclusion criteria were as follows: i) biopsy pathological proven malignancy; and ii) ultrasound criteria for malignancy (anteroposterior:transverse diameter ratio (A/T) >1, microcalcifications, marked hypoechoic, and ill-defined margins), although biopsy pathological result was benign.

**Preablation assessment** The diameters, composition, vascularity, and enhancement modality of nodules on ultrasound examination, laboratory data, and clinical symptoms were examined in all patients. All ultrasound examinations were performed on a real-time ultrasound system (Sequoia 512; Acuson, Mountain View, CA, USA). Three orthogonal diameters of thyroid nodules (the largest diameter and the two other perpendicular ones) were measured. The volume of the nodules was calculated by the following equation:  $V = \pi abc/6$  ( $V$ : volume,  $a$ : the largest diameter,  $b$  and  $c$ : the other two perpendicular diameters). The composition of the nodules was assessed by ultrasound examiner subjectively and was classified as mainly solid (having a solid portion >80%), mainly cystic (having a cystic portion >80%), or mixed type. Nodule vascularity was classified with a five-point scale: 0 (no color signal in nodule), 1 (a few spotty color signals in nodule), 2 (color signals in <25% of the nodule), 3 (color signals in 25–50% of the nodule), and 4 (color signals in >50% of the nodule) (5).

Laboratory tests including thyroid function (TSH, triiodothyronine (T<sub>3</sub>), free thyroxine (fT<sub>4</sub>)), complete blood count, and blood coagulation test (prothrombin time and activated partial thromboplastin time) were assessed. Fiber laryngoscopy was performed on all patients before MWA and on patients who complained of hoarseness or other symptoms related to nerve injury after MWA.

Clinical symptoms were evaluated using the symptom grading scores (visual analog scale, 0–10 cm), and the cosmetic grading score (grade 1: no palpable mass, grade 2: invisible but palpable mass, grade 3: visible mass only by experienced clinician's eyes, and grade 4: easily visible mass) (5).

**Procedure** All treatments were performed at our institution on an inpatient basis. The patient was placed in the supine position with hyperextended neck, and a venous catheter was inserted in a forearm vein. A multiparametric monitor was connected to the patient showing continuous blood pressure, pO<sub>2</sub>, and electrocardiogram. Local anesthesia with 1% lidocaine was given subcutaneously on the puncture site. A small incision <2 mm in length was made after local anesthesia. Ultrasound-guided biopsy was performed on all patients by the automatic biopsy instrument and

**Table 1** Coagulation lesion diameter of *ex vivo* with the same power 30 W. Data are mean values  $\pm$  s.d.

Energy	DI (cm)	Ds (cm)	Ratio of Ds:DI
30 W 3 min	1.8 $\pm$ 0.1	1.1 $\pm$ 0.1	0.6 $\pm$ 0.1
30 W 5 min	2.2 $\pm$ 0.2	1.4 $\pm$ 0.2	0.6 $\pm$ 0.1
30 W 7 min	2.1 $\pm$ 0.2	1.4 $\pm$ 0.0	0.7 $\pm$ 0.1
30 W 10 min	2.2 $\pm$ 0.1	1.5 $\pm$ 0.1	0.7 $\pm$ 0.1
30 W 12 min	2.5 $\pm$ 0.2	1.7 $\pm$ 0.3	0.7 $\pm$ 0.1

DI, long-axis diameter; Ds, short-axis diameter.

disposable core tissue biopsy needle (Bard, Tempe, AZ, USA). Then the internally cooled microwave antenna (16G) was placed into the thyroid nodule along its longest axis under ultrasound guidance by two of the experienced radiologists (P L, X L Y, Z G C, and Z Y H). After the antenna was placed at the designated site, unconscious i.v. anesthesia (propofol, 6–12 mg/kg per h; ketamine, 1–2 mg/kg) was administered via the forearm vein by an anesthesiologist. A power output of 20–30 W was used during MWA. The extent of ablation area was presumed by the echogenic change around the antenna. If the heat-generated hyperechoic water vapor did not completely encompass the entire nodule at one site, the tip of the antenna was moved backward. In cases of mainly cystic nodules, a percutaneous puncture needle (18G, Hakko Co., Chikuma-Shi, Japan) was inserted to the cystic portion and contained fluid was aspirated and then MWA was performed on the solid portion. At the end of the procedure, all patients remained under observation for 30 min with compression on the neck to prevent bleeding or hematoma formation.

**Postablation evaluation** Ultrasound examination, laboratory data, and clinical symptoms were evaluated 1 day, 1, 3, 6, 9, and 12 months after the procedure. The ultrasound examination was performed to assess the changes of MW-induced lesions, including the size, vascularity, echogenicity, and the enhancement modality. The volume reduction was calculated by the following equation: volume reduction ratio (%) = ((initial volume – final volume)  $\times$  100)/initial volume. The laboratory data such as T<sub>3</sub>, fT<sub>4</sub>, TSH, and the symptom grading score and cosmetic grading score were also evaluated and recorded at each follow-up. Side effects and complications of MWA were evaluated at the end of ablation as well as 24 h and 1 month after the procedure.

### Statistical analysis

Data analysis was performed with statistical software (SPSS for Windows version 13.0 SPSS Inc. Chicago, IL, USA). Values for quantitative variables were expressed as mean  $\pm$  s.d. and range. Differences in the long-axis diameter (DI), short-axis diameter (Ds), and Ds:DI ratio

between groups of *ex vivo* were evaluated by Kruskal–Wallis *H* test. Variables at enrollment and the follow-up visit were compared by Wilcoxon's signed rank test. Differences were considered significant when the *P* value was  $<0.05$ .

## Results

### Experimental study

All ablation lesions were ellipsoidal. Four well-defined zones of the ablated lesion were noted around the antenna: charring zone, coagulation zone, congestion zone, and normal liver parenchyma. The DI and Ds enlarged with the increase in microwave energy (Tables 1 and 2). The difference in Ds:DI ratio was not significant in groups either when the time was increased with the same power or the power was increased with the same time ( $P > 0.05$ ). The ablation lesion at 30 W 12 min tended to have appropriate scope and spherical shape, which provided a reference for clinical application. The DI, Ds, and ratio of Ds:DI of the ablation lesion at 30 W 12 min were 2.5 $\pm$ 0.2, 1.7 $\pm$ 0.3, and 0.7 $\pm$ 0.1 cm respectively. The mean temperature at 5 mm site from the electrode was driven rapidly high to 60 °C, which ensured tumor necrosis, while the maximum temperatures at 10 and 15 mm were low, which could guarantee the safety of surrounding tissue (Fig. 2).

### Clinical study

**Treatment characteristics** Ten lesions were completely ablated in a single session and one lesion at two sessions. A single antenna was used in nine patients and two antennae were used in two patients. The main power was 26 $\pm$ 4 (range, 20–30) W and total treatment time was 9.5 $\pm$ 4.7 (range, 4–16.5) min. For patient no. 4 with mainly cystic thyroid nodule, the obsolete bloody fluid (30 ml) was aspirated and then MWA (20 W 3 min, changed to 30 W 3 min) was performed on the solid portion (Fig. 3).

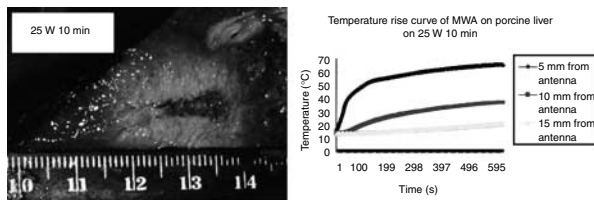
**Ultrasound, laboratory, and clinical results** Follow-up periods ranged from 1 to 9 months. The nodules were located in the left lobe in four cases, the right lobe in six cases, and the isthmus in one case. The

**Table 2** Coagulation lesion diameter of *ex vivo* with the same time 5 min. Data are mean values  $\pm$  s.d.

Energy	DI (cm)	Ds (cm)	Ratio of Ds:DI
20 W 5 min	1.7 $\pm$ 0.3	1.0 $\pm$ 0.1	0.6 $\pm$ 0.1
25 W 5 min	1.9 $\pm$ 0.1	1.3 $\pm$ 0.1	0.7 $\pm$ 0.1
30 W 5 min	2.2 $\pm$ 0.2	1.4 $\pm$ 0.2	0.6 $\pm$ 0.1

DI, long-axis diameter; Ds, short-axis diameter.





**Figure 2** Gross specimen and temperature rise curve of MWA in *ex vivo* porcine liver at 25 W 10 min. The long-axis diameter of the ablation lesion was 2.2 cm and the short-axis diameter was 1.2 cm. The mean temperature at 5 mm site from the electrode was driven rapidly high to 60 °C, which ensured tumor necrosis, while the maximum temperatures at 10 and 15 mm were low, which could guarantee the safety of surrounding tissue.

composition of the nodules was mainly solid ( $n=5$ ), mixed ( $n=5$ ), and mainly cystic ( $n=1$ ). After ablation, color Doppler ultrasound showed significant reduction of vascular signals (before vs after ablation,  $2.60 \pm 0.84$  vs  $0.40 \pm 0.52$ ,  $P < 0.01$ ). Nonenhancement was shown on contrast-enhanced ultrasound after treatment as a consequence of coagulative necrosis induced by MWA.

Because patient no. 4 was mainly cystic and was drained before MWA, the changes observed in this lesion were reported and evaluated separately (Tables 3 and 4). For other patients, the largest diameter of the nodules decreased from  $2.9 \pm 1.0$  (range, 1.6–4.1) cm before ablation to  $1.9 \pm 0.7$  (range, 0.4–3.0) cm at the last follow-up ( $P < 0.01$ ). The volume decreased from  $5.30 \pm 4.88$  (range, 0.89–14.81) ml before ablation to  $2.40 \pm 2.06$  (range, 0.02–6.35) ml at the last follow-up ( $P < 0.01$ ). The volume reduction was  $45.99 \pm 29.90$  (range, 10.56–98.15) % at the last follow-up (Table 4).

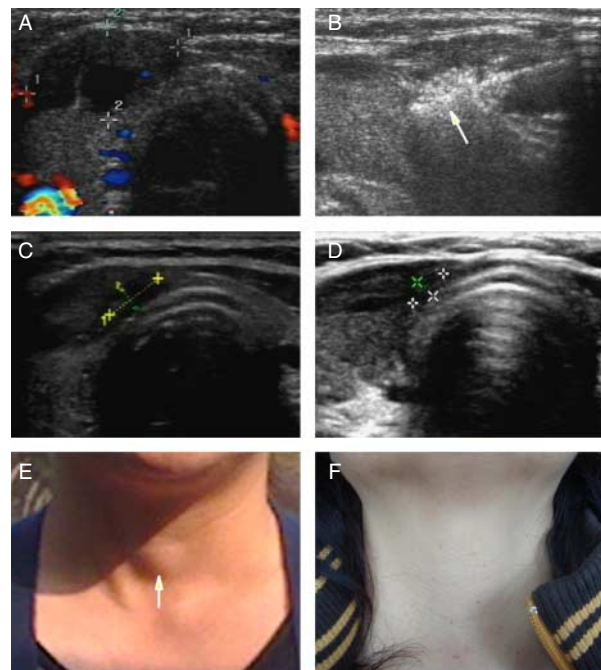
Initial mean  $T_3$ ,  $fT_4$ , and TSH were  $1.68 \pm 0.23$  nmol/l,  $15.38 \pm 2.65$  pmol/l, and  $2.71 \pm 1.96$  mU/l respectively. A significant change of mean  $fT_4$  and TSH was observed 1 day after ablation ( $fT_4$ :  $18.08 \pm 2.64$  pmol/l,  $P < 0.05$ ; TSH:  $1.42 \pm 1.78$  mU/l,  $P < 0.01$ ). Serum  $T_3$  did not change ( $T_3$ :  $2.02 \pm 0.60$  nmol/l,  $P > 0.05$ ). The symptom grading score was reduced from  $1.20 \pm 1.87$  to  $0.40 \pm 0.70$  ( $P > 0.05$ ), and cosmetic grading score was reduced from  $3.20 \pm 0.79$  to  $2.30 \pm 0.95$  ( $P < 0.05$ ).

**Side effects and complications** After MWA, eight patients complained of a sensation of heat in the neck and/or slight pain at the ablated site. All patients could tolerate the symptoms needing no analgesics. During or immediately after ablation, mild bleeding (thyroid capsule hemorrhage  $< 1$  mm on ultrasound) developed in four patients. Slight fever ( $37$ – $37.5$  °C) was found in three patients lasting 1 day. One patient complained of coughing and choking when drinking (so she could not drink water) and a little voice change 6 h after ablation. Laryngoscopic evaluation demonstrated ipsilateral vocal cord palsy. She could drink water and her voice recovered within 2 months after corticosteroids,

physical therapy, water training, and vocal exercises. There were no complications such as esophageal perforation, tracheal injury, infection, or skin burn.

## Discussion

As the first trial of ethanol injection to an autonomous thyroid nodule in 1990 (12), many investigators have used this agent as an alternative therapeutic procedure in various benign thyroid diseases (3, 13, 14, 15). The results have confirmed that percutaneous ethanol injection is effective for nodule volume reduction, but ethanol injection has side effects related to the leakage of ethanol outside the capsule of the nodule and the need for multiple ethanol injection. The side effects of ethanol injection include extraglandular fibrosis, vocal chord paresis, hematoma, abscess, dysphagia, and mild to severe pain (3, 15). Thermal ablation such as laser and RFA is a recently developed procedure (2, 4, 5, 16, 17) and the advantage includes a well-defined area of complete tissue ablation with a regular, homogeneous, and reproducible pattern (17). However, laser ablation requires up to three sessions or the insertion of multiple fibers for treating large nodules, which increases the risk of local adverse events (18).



**Figure 3** Transverse US scans of the neck of a 53-year-old treated female patient showed a mixed nodule in the thyroid isthmus before (a, 0.92 ml), 3 months (c, 0.14 ml), and 9 months (d, 0.02 ml) after MWA. (b) During the procedure, multiple echogenic microbubbles (arrow) around the antenna tip were noted. (e) Before MWA, an almond-sized nodule could be seen outside the skin of neck (arrow) and tenderness could be felt. (f) Three months after MWA, the thyroid nodule completely disappeared and no scars were left on the neck. Full colour version of this figure available via <http://dx.doi.org/10.1530/EJE-11-0966>.

**Table 3** Characteristics of patient population and MWA treatment.

Patient no.	Age (years)	Biopsy pathological findings	Composition	MW antennae	Ablation time (min)	Vascularity	
						Before	After
1	F/53	Nodular goiter	Mixed	1	4	1	1
2	F/47	Nodular goiter	Mainly solid	2	16.5	3	0
3	F/52	Nodular goiter	Mixed	2	15	4	0
4	M/49	Nodular goiter	Mainly cystic	1	6	1	0
5	F/57	Hashimoto's thyroiditis	Mainly solid	1	5	3	1
6	F/59	Nodular goiter	Mainly solid	1	8	2	0
7	F/59	Hashimoto's thyroiditis	Mainly solid	1	10.5	3	0
8	F/39	Nodular goiter	Mixed	1	14	2	0
9	F/47	Nodular goiter	Mainly solid	1	5	3	1
10	F/48	Nodular goiter	Mixed	1	14	2	0
11	F/41	Nodular goiter	Mixed	1	6	3	1

MWA has been used to treat hepatocellular carcinoma in our department with a 5-year survival rate comparable to that of hepatectomy for small hepatocellular carcinoma (6). We mostly used microwave antenna 11 mm from the narrow radiating segment to the tip with 2450 MHz applicator to treat abdominal tumors (19, 20). However, thyroid nodules are different from abdominal tumors on account of superficial location, thin thyroid gland, usually small tumors, and surrounding vital structures. The internally cooled needle antenna in this study is modified specially to treat superficial neck organ diseases, which has finer diameter, shorter shaft, and closer distance from the narrow radiating segment to the tip.

Laser and RFA, techniques using thermal injury to destroy tissue, obtain variable nodule volume reduction (2, 4, 5, 17, 18, 21, 22). The mean volume reduction ratio in laser ablation was 44.0–74.3% (4, 17, 23, 24), while in RFA, it ranged from 50.9 to 91.3% (21, 25, 26, 27, 28). In our study, the mean nodule volume reduction ratio was 45.99% and the cosmetic grading score was reduced significantly at the last follow-up.

The mixed or mainly cystic nodules showed a better treatment response than the mainly solid tumors. This might be due to the homogeneous conduction of heat, the absence of a heat sink effect, and removal of the cystic component (2). In this study, serum TSH levels significantly decreased ( $P < 0.01$ ),  $fT_4$  levels significantly increased ( $P < 0.05$ ), and serum  $T_3$  did not change ( $P > 0.05$ ) 1 day after MWA. It was likely that ablation-induced  $fT_4$  release from intraglandular stores and serum TSH level decreased due to feedback regulation (4).

The side effect and complication rate in this preliminary study were higher than what was published with the other ablation techniques (2, 4, 16, 17, 22), and it partly related to the use of a thick device for MWA. The 16G antenna used in the study was more invasive than the 17G needle used for RFA (22) and 21G needle for laser ablation (29). Nerve injury was the most serious complication in our study. Iatrogenic nerve injury cannot be avoided completely even in the surgical field where the nerve trunk can be identified with the naked eye. The average incidence of temporary

**Table 4** Pretreatment and posttreatment clinical data on patients with MWA. Normal range:  $T_3$  1.01–2.95 nmol/l,  $fT_4$  10.42–24.32 pmol/l, and TSH 0.35–5.5 mU/l.

Patient no.	Follow-up (m)	$T_3$ (nmol/l)		$fT_4$ (pmol/l)		TSH (mU/l)		Symptom		Cosmetic		Volume (ml)		Reduction (%)
		Initial	Last	Initial	Last	Initial	Last	Initial	Last	Initial	Last	Initial	Last	
1	9	1.28	1.38	15.88	14.28	2.07	1.19	2	1	4	1	0.92	0.017	98.15
2	1	1.86	2.25	16.02	20.88	0.56	0.11–	4	2	2	2	5.49	4.91	10.56
3	6	1.82	1.72	14.60	16.31	0.53	0.44	0	0	2	1	12.82	0.711	94.45
4 <sup>a</sup>	4	1.71	2.15	15.79	17.65	3.03	1.51	0	0	3	2	29.13	3.76	87.09
5	1	1.64	1.43	12.35	17.30	6.24+	6.17+	0	0	3	2	2.72	1.5	44.85
6	3	1.64	1.52	21.27	19.36	1.83	0.59	1	0	4	3	6.2	3.43	44.68
7	1	1.69	2.72	11.23	16.50	5.83+	2.17	0	0	3	2	0.89	0.75	15.73
8	3	1.54	1.88	15.75	19.05	2.26	0.34–	5	1	3	3	4.82	3.38	29.88
9	6	1.53	1.79	16.29	14.74	2.57	1.48	0	0	3	2	1.51	1.09	27.81
10	1	1.66	2.25	15.15	21.93	3.50	1.19	0	0	4	3	2.81	1.78	36.65
11	3	2.14	3.21+	15.22	20.45	1.68	0.51	0	0	4	4	14.81	6.35	57.12

+ , higher than normal range; – , lower than normal range.

<sup>a</sup>For patient no. 4 with mainly cystic thyroid nodule, the obsolete bloody fluid (30 ml) was aspirated and then microwave ablation (20 W 3 min, changed to 30 W 3 min) was performed on the solid portion.

recurrent laryngeal nerve palsy after thyroidectomy is 9.8% and the incidence of permanent palsy is 2.3% (30). Transient recurrent laryngeal nerve palsy rate in video-assisted thyroid lobectomy was 2.6% (31). Previous studies using radiofrequency or laser ablation described the incidence of transient or permanent nerve injury to be 0–8.3% (2, 4, 17, 18, 21, 22, 24, 25). The most likely explanation for nerve injury in thermal ablation was thermal injury directly or nerve compression caused by perinodular edema. To decrease the incidence of nerve injury, the following aspects can be considered: first, if there are nodules on both lobes of the thyroid gland, perform MWA on the nodule on one side at a session to avoid nerve injury of both sides that cannot be compensated; secondly, complete ablation of the whole nodule is not always necessary if thyroid benign nodules are too close to the nerve; thirdly, temperature monitoring or infusion of saline into the surrounding thyroid capsule was necessary to protect the nerve from thermal injury.

In conclusion, our experimental and clinical results suggest that the modified superficial tissue microwave antenna can yield ablation lesions with ideal shape and appropriate scope, and ultrasound-guided percutaneous MWA is a feasible technique for cytologically benign thyroid nodules. However, this procedure should be performed by trained doctors experienced in neck anatomy, ultrasound scanning, and MWA. The limitations of this study are the small case number and short follow-up period, so further study with large samples and long-term follow-up will be necessary.

### Declaration of interest

The authors declare that there is no conflict of interest that could be perceived as prejudicing the impartiality of the research reported.

### Funding

This work was supported by the National Scientific Foundation Committee of China (grant numbers 30825010, 81071210).

### References

- Gharib H, Papini E, Paschke R, Duick DS, Valcavi R, Hegedus L & Vitti P. American Association of Clinical Endocrinologists, Associazione Medici Endocrinologi, and European Thyroid Association medical guidelines for clinical practice for the diagnosis and management of thyroid nodules. *Journal of Endocrinological Investigation* 2010 **33** 1–50.
- Jeong WK, Baek JH, Rhim H, Kim YS, Kwak MS, Jeong HJ & Lee D. Radiofrequency ablation of benign thyroid nodules: safety and imaging follow-up in 236 patients. *European Radiology* 2008 **18** 1244–1250. (doi:10.1007/s00330-008-0880-6)
- Tarantino L, Giorgio A, Mariniello N, de Stefano G, Perrotta A, Aloisio V, Tamasi S, Forestieri MC, Esposito F, Finizia L & Voza A. Percutaneous ethanol injection of large autonomous hyperfunctioning thyroid nodules. *Radiology* 2000 **214** 143–148.
- Valcavi R, Riganti F, Bertani A, Formisano D & Pacella CM. Percutaneous laser ablation of cold benign thyroid nodules: a 3-year follow-up study in 122 patients. *Thyroid* 2010 **20** 1253–1261. (doi:10.1089/thy.2010.0189)
- Baek JH, Kim YS, Lee D, Huh JY & Lee JH. Benign predominantly solid thyroid nodules: prospective study of efficacy of sonographically guided radiofrequency ablation versus control condition. *AJR. American Journal of Roentgenology* 2010 **194** 1137–1142. (doi:10.2214/AJR.09.3372)
- Liang P, Wang Y, Yu X & Dong B. Malignant liver tumors: treatment with percutaneous microwave ablation – complications among cohort of 1136 patients. *Radiology* 2009 **251** 933–940. (doi:10.1148/radiol.2513081740)
- Liang P, Gao Y, Zhang H, Yu X, Wang Y, Duan Y & Shi W. Microwave ablation in the spleen for treatment of secondary hypersplenism: a preliminary study. *AJR. American Journal of Roentgenology* 2011 **196** 692–696. (doi:10.2214/AJR.10.4193)
- Wang Y, Liang P, Yu X, Cheng Z, Yu J & Dong J. Ultrasound-guided percutaneous microwave ablation of adrenal metastasis: preliminary results. *International Journal of Hyperthermia* 2009 **25** 455–461. (doi:10.1080/02656730903066608)
- Liang P, Wang Y, Zhang D, Yu X, Gao Y & Ni X. Ultrasound guided percutaneous microwave ablation for small renal cancer: initial experience. *Journal of Urology* 2008 **180** 844–848 (discussion 848). (doi:10.1016/j.juro.2008.05.012)
- Wolf FJ, Grand DJ, Machan JT, Dipetrillo TA, Mayo-Smith WW & Dupuy DE. Microwave ablation of lung malignancies: effectiveness, CT findings, and safety in 50 patients. *Radiology* 2008 **247** 871–879. (doi:10.1148/radiol.2473070996)
- Wright AS, Sampson LA, Warner TF, Mahvi DM & Lee FT Jr. Radiofrequency versus microwave ablation in a hepatic porcine model. *Radiology* 2005 **236** 132–139. (doi:10.1148/radiol.2361031249)
- Livraghi T, Paracchi A, Ferrari C, Bergonzi M, Garavaglia G, Raineri P & Vettori C. Treatment of autonomous thyroid nodules with percutaneous ethanol injection: preliminary results. Work in progress. *Radiology* 1990 **175** 827–829.
- Verges B, Buffier P, Baillet-Rudoni S, Brindisi MC, Bouillet B & Petit JM. Non-ultrasound-guided ethanol sclerotherapy for the treatment of thyroid cysts. *Annales d'Endocrinologie* 2011 **72** 203–207. (doi:10.1016/j.ando.2011.04.007)
- Song DE, Kim YM & Gong G. Cytomorphological changes after ultrasound-guided percutaneous ethanol injection in benign thyroid nodules. *Cytopathology* 2009 **20** 183–187. (doi:10.1111/j.1365-2303.2008.00556.x)
- Tarantino L, Francica G, Sordelli I, Sperlongano P, Parmeggiani D, Ripa C & Parmeggiani U. Percutaneous ethanol injection of hyperfunctioning thyroid nodules: long-term follow-up in 125 patients. *AJR. American Journal of Roentgenology* 2008 **190** 800–808. (doi:10.2214/AJR.07.2668)
- Pacella CM, Bizzarri G, Guglielmi R, Anelli V, Bianchini A, Crescenzi A, Pacella S & Papini E. Thyroid tissue: US-guided percutaneous interstitial laser ablation – a feasibility study. *Radiology* 2000 **217** 673–677.
- Spiezia S, Vitale G, Di Somma C, Pio Assanti A, Ciccirelli A, Lombardi G & Colao A. Ultrasound-guided laser thermal ablation in the treatment of autonomous hyperfunctioning thyroid nodules and compressive nontoxic nodular goiter. *Thyroid* 2003 **13** 941–947. (doi:10.1089/105072503322511346)
- Dossing H, Bennedbaek FN & Hegedus L. Long-term outcome following interstitial laser photocoagulation of benign cold thyroid nodules. *European Journal of Endocrinology* 2011 **165** 123–128. (doi:10.1530/EJE-11-0220)
- Liang P, Dong B, Yu X, Yu D, Wang Y, Feng L & Xiao Q. Prognostic factors for survival in patients with hepatocellular carcinoma after percutaneous microwave ablation. *Radiology* 2005 **235** 299–307. (doi:10.1148/radiol.2351031944)
- Liu FY, Yu XL, Liang P, Wang Y, Zhou P & Yu J. Comparison of percutaneous 915 MHz microwave ablation and 2450 MHz

- microwave ablation in large hepatocellular carcinoma. *International Journal of Hyperthermia* 2010 **26** 448–455. (doi:10.3109/02656731003717574)
- 21 Spiezia S, Garberoglio R, Milone F, Ramundo V, Caiazza C, Assanti AP, Deandrea M, Limone PP, Macchia PE, Lombardi G, Colao A & Faggiano A. Thyroid nodules and related symptoms are stably controlled two years after radiofrequency thermal ablation. *Thyroid* 2009 **19** 219–225. (doi:10.1089/thy.2008.0202)
- 22 Kim YS, Rhim H, Tae K, Park DW & Kim ST. Radiofrequency ablation of benign cold thyroid nodules: initial clinical experience. *Thyroid* 2006 **16** 361–367. (doi:10.1089/thy.2006.16.361)
- 23 Dossing H, Bennedbaek FN & Hegedus L. Effect of ultrasound-guided interstitial laser photocoagulation on benign solitary solid cold thyroid nodules – a randomised study. *European Journal of Endocrinology* 2005 **152** 341–345. (doi:10.1530/eje.1.01865)
- 24 Pacella CM, Bizzarri G, Spiezia S, Bianchini A, Guglielmi R, Crescenzi A, Pacella S, Toscano V & Papini E. Thyroid tissue: US-guided percutaneous laser thermal ablation. *Radiology* 2004 **232** 272–280. (doi:10.1148/radiol.2321021368)
- 25 Jang SW, Baek JH, Kim JK, Sung JY, Choi H, Lim HK, Park JW, Lee HY, Park S & Lee JH. How to manage the patients with unsatisfactory results after ethanol ablation for thyroid nodules: role of radiofrequency ablation. *European Journal of Radiology* 2012 In Press.
- 26 Park KW, Shin JH, Han BK, Ko EY & Chung JH. Inoperable symptomatic recurrent thyroid cancers: preliminary result of radiofrequency ablation. *Annals of Surgical Oncology* 2011 **18** 2564–2568. (doi:10.1245/s10434-011-1619-1)
- 27 Baek JH, Moon WJ, Kim YS, Lee JH & Lee D. Radiofrequency ablation for the treatment of autonomously functioning thyroid nodules. *World Journal of Surgery* 2009 **33** 1971–1977. (doi:10.1007/s00268-009-0130-3)
- 28 Deandrea M, Limone P, Basso E, Mormile A, Ragazzoni F, Gamarra E, Spiezia S, Faggiano A, Colao A, Molinari F & Garberoglio R. US-guided percutaneous radiofrequency thermal ablation for the treatment of solid benign hyperfunctioning or compressive thyroid nodules. *Ultrasound in Medicine & Biology* 2008 **34** 784–791. (doi:10.1016/j.ultrasmedbio.2007.10.018)
- 29 Papini E, Guglielmi R, Hosseim G, Misischi I, Graziano F, Chianelli M, Crescenzi A, Bianchini A, Valle D & Bizzarri G. Ultrasound-guided laser ablation of incidental papillary thyroid microcarcinoma: a potential therapeutic approach in patients at surgical risk. *Thyroid* 2011 **21** 917–920. (doi:10.1089/thy.2010.0447)
- 30 Jeannon JP, Orabi AA, Bruch GA, Abdalsalam HA & Simo R. Diagnosis of recurrent laryngeal nerve palsy after thyroidectomy: a systematic review. *International Journal of Clinical Practice* 2009 **63** 624–629. (doi:10.1111/j.1742-1241.2008.01875.x)
- 31 Yamashita H, Watanabe S, Koike E, Ohshima A, Uchino S, Kuroki S, Tanaka M & Noguchi S. Video-assisted thyroid lobectomy through a small wound in the submandibular area. *American Journal of Surgery* 2002 **183** 286–289. (doi:10.1016/S0002-9610(02)00801-2)

---

Received 9 November 2011

Revised version received 27 February 2012

Accepted 23 March 2012